

## SUCCESSFUL TREATMENT OF NEVUS OF OTA BY QS ALEXANDRITE LASERS (755 nm)

Nguyen Huu Sau<sup>1,2\*</sup>, Nguyen The Vy<sup>3</sup>,  
Vu Manh Hung<sup>3</sup>, Nguyen Quoc Hung<sup>3</sup>

<sup>1</sup>*Hanoi Medical University Vietnam;*

<sup>2</sup>*National Hospital of Dermatology and Venereology - Vietnam;*

<sup>3</sup>*Hanoi city Hospital of Dermatology and Venereology*

*e-mail: nguyenhhusau@yahoo.com*

### Abstract

Nevus of Ota is a facial congenital pigmentation disorder affecting mainly the face. Nowadays, different types of pigmentation lasers have been used to treat Nevus of Ota. Very few research to address the treatment results have been performed in Vietnam. Objective: To evaluate the clinical efficacy of Qs Alexandrite lasers in treatment of Nevus of Ota in Vietnamese people. Method: 35 patients with Nevus of Ota were treated by 8 sessions of Qs Alexandrite laser 755 nm at monthly intervals. Clinical improvement was evaluated based on color of the Nevus of Ota before, during and after treatment. Results: The color of Nevus of Ota gradually improved after 2, 4, 6, 8 sessions. After 8 sessions of treatment, excellent improvement accounted for 45,7%, and there was no case of slight improvement. 100% brown nevus achieved excellent improvement, while dark blue nevus improved 35,7%. Only 29% Nevus of Ota at the eyelids was found with hyperpigmentation after treatment. 94,2% patients were satisfied with the treatment. Conclusion: The laser targets in Nevus of Ota are melanocytes and dermal melanosomes. After treatment, the skin structure returns to normal appearance.

---

<sup>1</sup>Corresponding author. **Key words:** Nevus of Ota, congenital pigmentation disorder, Qs Alexandrite laser, ultrastructure, Vietnam

## 1. Introduction

Nevus of Ota is a congenital pigmentation disorder affecting mainly the face, described by Ota in 1939[4]. The clinical manifestation of the disease is the hyperpigmented patches on the face [5, 12]. Nevus of Ota affects not only health but especially the aesthetics and psychology of patients, which leads to lack of confidence in their life. Pathologically, it is a dermal melanocytic hematoma that is manifested with unilateral or bilateral, brown or blue discoloration on the facial skin, innervated by the trigeminal nerve.

To date, different types of pigmentation lasers have been applied in the treatment of Nevus of Ota[2, 6]. In the early phase, cryosurgery, surgical excision, skin grafting and dermabrasion are typically employed. Since the development of laser technology, several lasers have been introduced to the treatment of benign pigmented lesions, such as Q- switched lasers which have been used to treat Nevus of Ota. Some studies have demonstrated that Laser QS Alexandrite with the wavelengths of 1064 nm and 532 nm is the most effective and widely-used method for treating the Nevus of Ota[1, 8, 9]. The AlexTriVantage with a long-pulse 755 nm is also used for the treatment of pigmented lesions without unwanted pigment changes.

In Viet Nam, the need for treatment of Nevus of Ota has increased over the past few years. The aim of the research was to investigate the efficacy of AlexTriVantage with a long-pulse 755 nm in the treatment of Nevus of Ota in Vietnamese people and the histological alteration of Nevus of Ota treated by Laser QS Alexandrite.

## 2. Material and methods

Patients with Nevus of Ota at Hanoi Dermatology Hospital were recruited and informed consent obtained from them before the laser treatment. The characteristics about sex, age of onset, color, location of the lesions were recorded. The area to be treated was applied with topical anesthesia using EMLA 5% cream. The eyes of the patients were protected with goggles. The lesions were treated by lasers AlexTriVantage (Candela Canada) with wavelength 755nm, power 5- 8j/cm<sup>2</sup> for 8 sessions, with an interval of 4 -12 weeks between sessions. After the procedure, all patients were asked to avoid unnecessary sun exposure. Non combination treatment was indicated after the laser treatment once the scabs had fallen off along with daytime use of sunscreen. The final results were analyzed after 2, 4, 6, 8 sessions of treatment.

Clinical assessments were performed by dermatologists and the improvement in the color of the lesions were recorded by using spectrophotometer Colorlite 900. The difference between the lesions and normal skin (opposite side of face . this is also the expected color after treatment) is described by  $\Delta E$  index.

The  $\Delta E$  index is considered as 100%. There are 4 degrees of evaluation: very good:  $\Delta E$  index. 80% normal skin index; good: 60-79%; medium: 40-59%; bad: < 40%. The ultrastructural changes of melanocytes and melanosomes were observed before, during, after treatment using optical microscopy and electron microscopy JM 1410. Photographs were taken before each treatment. Private information of patients was kept confidential. The data were only used for research purposes.

### 3. Results

There were 35 patients recruited for the study; two thirds of the patients were female and 65,7% were aged from 10 to 29 years. Clinical assessment of effectiveness based on the change in color in 35 patients before and after treatment as well as ultrastructural changes before, during, after treatment of 20 skin biopsies: the color of Nevus of Ota of all patients improved gradually after 2, 4, 6, 8 sessions of treatment. After 8 treatment sessions the improvement in the color of the nevus at very good, good, average levels was respectively 45.7%; 51.4% and 2.9%. There was complete clearance (100%) of all brown lesions, while 35.7% of black blue nevus had completely disappeared. Only 29.0% of nevus located on eyelids had a very good level (Table 1).

Table 1. The color improvement of Nevus of Ota after treatment (n=35)

Improvement		Excellent	Good	Moderate	Partial improvement	Total
After 2 sessions	n	0	0	2	33	35
	%	0	0	5,7	94,3	100
After 4 sessions	n	2	4	9	20	35
	%	5,7	11,5	25,7	57,1	100
After 6 sessions	N	5	12	16	2	35
	%	14,3	34,3	45,7	5,8	100
After 8 sessions	N	16	18	1	0	35
	%	<u>45,7</u>	51,4	2,9	0	100

In investigating the side effects of the treatment we found that there were only 2 patients (5.8%) who suffered unwanted transient hyperpigmentation which appeared after the second session. No patients experienced hypopigmentation or atrophic scarring (Table 2). We also noted that 94.2% of patients were satisfied with the treatment. Two patients who had transient pigmentary change were not satisfied with the results at the end of treatment.

#### **Histopathological manifestations of Nevus of Ota pre- and post-therapy.**

Histological improvement was evaluated based on the ultrastructural alter-

Table 2. Side effects and satisfaction levels of patients after treatment

		n	%
Side effects	Hyperpigmentation	2	5,8
	Hypopigmentation	0	0
	Scarring	0	0
Satisfaction	Very satisfied	19	54,2
	Satisfied	14	40,0
	Not satisfied	2	5,8
<b>Total</b>		35	100

ations with 20 skin biopsy samples taken from 35 patients. Before the treatment we found melanocytes clustered at the basal layer of epidermis as well as in the dermal zone between the collagen; large melanosomes were mostly at stages III, IV concentrated surround the nuclear. After treatment, melanosomes in the dermal melanocytes were destroyed and melanocytes had degenerated. However, the structure of the epidermis was nearly normal (Table 3; Fig 1).

#### 4. Discussion

The level of improvement in treating Nevus of Ota increased gradually after 2, 4, 6, 8 sessions. After 8 sessions, the number of patients who achieved excellent improvement in color accounted for 31,4% and 45,7%, respectively. There were no cases of slight improvement. Our study validates the usefulness of QS lasers as a single effective treatment modality for Nevus of Ota, as the results reveal a significant improvement in patients treated with lasers AlexTrivantage with wavelength 755nm.

According to the laser practitioner’s experience, available equipment and preference, several laser modalities were used, including QS neodymium-doped yttrium aluminum garnet (Nd:YAG) lasers, picosecond-domain Nd:YAG laser (PNY) and 1,064 nm long-pulsed Nd:YAG laser, 755 nm Alexandrite (AL) and 1,064 nm long-pulsed Nd:YAG lasers. Most studies revealed that these lasers are suitable in the treatment of Nevus of Ota.

G.A. Moreno-Arias et al. treated Nevus of Ota by Qs Alexandrite laser with 8 sessions. The results revealed 100% patients were satisfied with the treatment, while 76,92 % Nevus of Ota showed excellent and good improvement [9].

Henry H. Chan compared the efficacy and side effects of Qs YAG laser with Qs Alexandrite laser in treating Nevus of Ota. Results showed that 20% patients treated by Qs YAG laser and 16,9% patients treated by Qs Alexandrite laser showed more than 75% improvement. 21% patients treated by Qs YAG

Table 3. Histopathological manifestations of Nevus of Ota pre- and post-therapy.

	<b>Microscopy</b>	<b>Ultrastructure</b>	<b>Microscopy</b>	<b>Ultrastructure</b>
Before treatment	Hyperpigmentation in stratum corneum and basal layers of epidermis. melanocytes clustered at the basal layer and between the collagen in the dermis	Increasing the number of melanocytes and the concentration of melanosomes.	Melanocytes densely concentrated (abnormal)	Melanocytes have melanosomes at various stages, especially at III, IV. Diameter of melanosomes are larger than that in epidermis
Immediately after treatment	Keratinocytes and melanocytes are damaged.	Damage of keratinocyte, melanocytes: vacuolation; swelling of ribosome, mitochondries; inhomogeneous  Melanosomes; there is a decrease, even an absence in the center, create spaces inside melanosome.	Melanocytes are damaged	Melanocytes are severely damaged: there are vacuoles in plasma; cellular membrane is intermittent. Melanosome is destroyed or broken apart, vacuolated. Destroyed melanosomes escaped in intercellular spaces, between collagen fibers.
1-2 months after treatment	Keratinocytes and melanocytes have recovered	Melanosome degeneration	Inflammatory cells	melanosome degeneration and infiltration of inflammatory cells
3-4 months after treatment	Keratinocytes and melanocytes are normal	Melanosomes are nearly normal	Reduced inflammatory response	Melanosome degradation still occurs but less than 1-3 months.
After 8 months treatment	Normal epidermal structure	Melanosome recovered fully in melanocytes and keratinocytes	No or very little melanocytes	Few melanosomes in the dermis

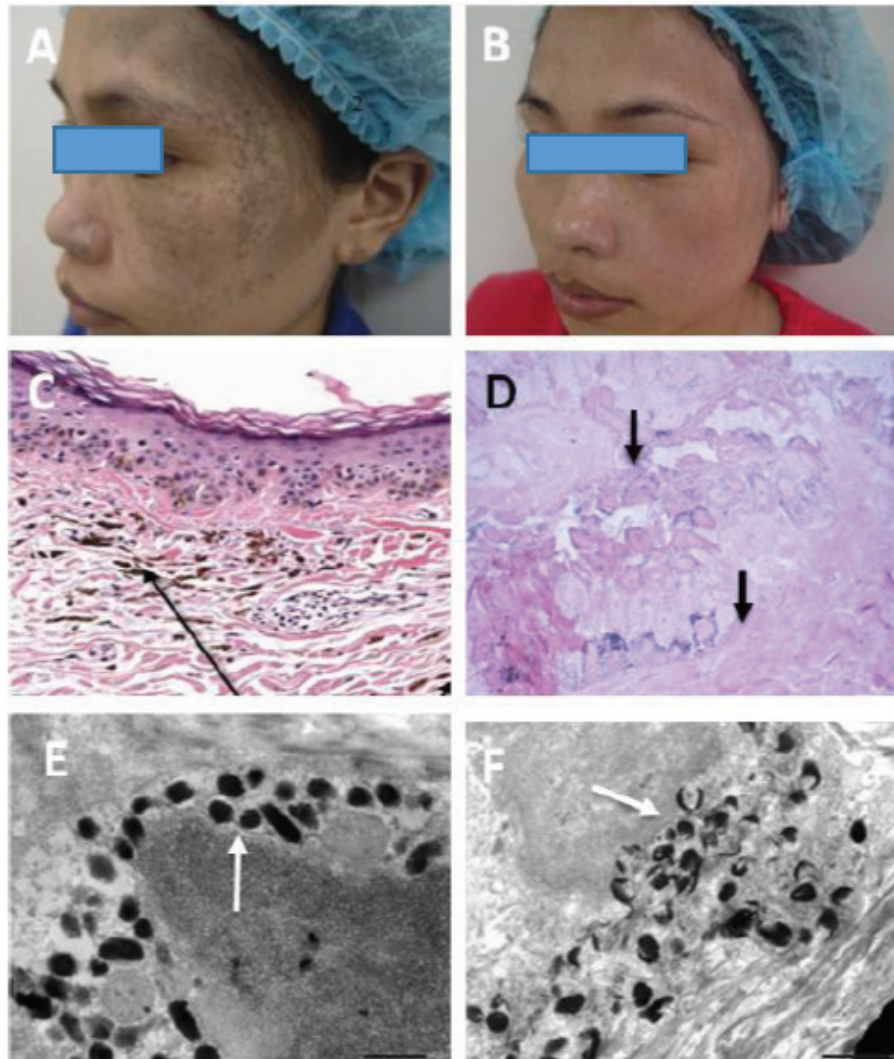


Figure 1: A. clinical features before treatment; B. after 8 sessions of treatment at one month intervals; C. many melanocytes are concentrated at in dermal layer (black arrow, H&E stains; x 200); D. alteration of the skin immediately after treatment with an unstructured area in epidermis and disarranged cells (black arrow, Masson-Fontana stain) (x 400); E. melanosomes density around the nuclear of melanocyte in the dermal layer of Nevus of Ota before treatment (white arrow, TEM x 10.000, scale bar = 500nm); F. melanosomes destroyed by laser beam with nuclear membrane damage (white arrow, TEM x 5.000, scale bar = 1,0 nm).

laser and 19% patients treated by Qs Alexandrite lasers showed between 50 and 75% improvement [3].

Hong-Weiwang et al., who treated 602 Chinese patients with Nevus of Ota by Qs Alexandrite laser, showed 85,2% improvement, in which 55,7% patients recovered completely[12].

The AlexTriVantage builds upon the proven performance of our 755 nm, Q-switched Alexandrite laser with the addition of 1064 nm and 532 nm Q-switched Nd:YAG wavelengths. This remarkable new configuration also offers a Long-Pulse 755 nm wavelength, providing treatment for a greater variety of pigmented lesions without unwanted pigment changes.

The level of color improvement of Nevus of Ota has been gradually increased, dark blue, violet blue, violet brown and brown. Our study had similar results. Sueda, M.isoda evaluated the correlation between color and result treatment on 151 patients and concluded that excellent and good improvement occurred essentially in the brown and violet brown lesions[11]. N-K.Rho, W-S.Kim analyzed 40 skin biopsy samples. They realized the penetration of melanin and melanocytes with brown nevus was more superficial than dark blue nevus[10]. It seems that lasers act better with the melanocytes in the superficial layer of the dermis.

In our study, the color and area of Nevus of Ota at the eyelids improved less than that at the cheek, temple and forehead. Our results were correlated with others[7]. Henry H. Chan et al. realized that Nevus of Ota at the eyelids (Panda sign) improved less than at other sites treated by pigmentation lasers[3]. It is possible that the structure of the eyelids is thinner and it becomes edema immediately after laser, thus preventing the laser rays from penetrating deeper inside.

In most studies, transient pigmentation changes were identified, ranging from 8% to 25.1%, which were consistent with that of 5.8% in our study, which showed gradual improvements with time. Hong-Weiwang, Yue-Hualiu analyzed 602 patients treated by Qs Alexandrite laser. They realized that most patients did not have any complications after treatment. Hyperpigmentation and hypopigmentation accounted for 1% and 1.5% respectively[12]. It is considered that treating Nevus of Ota by Qs Alexandrite laser has not had significant complications in most cases.

Our study realized that Nevus of Ota was specific by hyperpigmentation in basal cell area and there was dense appearance of melanocytes and melanosomes, the focus on dermal area. When treated by laser, the cells containing melanosome were destroyed, including hepatocytes, epidermal melanocytes and dermal melanocytes. However, they realized that the hepatocytes and epidermal

melanocytes were restored completely after 3-4 months, melanosomes returned to normal appearance, and epidermis returned to normal appearance after 6 months. Meanwhile, melanocytes and melanosome of dermis were damaged and degenerated, which brought about concentration of macrophages, lymphocytes and fibroblast phagocytosed. The process of degenerated melanosomes and

phagocytized occurred continuously due to the sessions being consecutive. Dermal melanocytes and melanosomes reduced gradually after every treatment. Thus the targets of Qs Alexandrite laser are melanocytes and dermal melanosomes. This was proven more clearly when analyzing skin samples after finishing treatment. The results were excellent: the epidermal area was completely normal, the dermal area had mostly no melanocytes and melanosomes, but elastin and collagen were still arranged in some confusion after 6 months treatment. After 12 months treatment, clinical features recovered and the skin structure returned to its normal appearance in superstructure, and no complications were reported.

## 5. Conclusion

Qs Alexandrite lasers are an effective and safe treatment for Nevus of Ota. The targets of Qs Alexandrite laser are melanosomes of dermal melanocytes. After treatment, the melanocytes and dermal melanosomes were destroyed; however, the epidermal melanocyte were unaffected.

**Funding:** No funding was received.

**Conflict of interest:** The authors declare that they have no conflict of interest.

**Ethical approval:** All procedures performed in studies involving human participants were in accordance with the ethical standards of institutional and/or national research committee and with the 1964 Helsinki declaration and its later amendments or comparable ethical standards. This study was approved by institutional review board of two hospitals of Hanoi city Hospital of Dermatology and Venereology and National Hospital of Dermatology and Venereology- Vietnam.

**Informed consent:** Informed consents were obtained from the patients or their relatives included in the study.

## References

- [1] M. Alam, K.A. Arndt, J.S. Dover, *Laser treatment of nevus of Ota*, *Dermatologic Therapy* **14** (2001) 55-59.
- [2] H.H. Chan, W.W. King, E.S. Chan, C.O. Mok, W.S. Ho, C. Van Kreveld, W.Y. Lau, *In vivo trial comparing patients' tolerance of Q-switched Alexandrite (QS Alex) and Q-*



- switched neodymium:yttrium-aluminum-garnet (QS Nd:YAG) lasers in the treatment of nevus of Ota*, Lasers Surg Med. **24** (1999) 24-28.
- [3] H.H. Chan, L.K. Lam, D.S. Wong, R.S. Leung, S.Y. Ying, C.F. Lai, W.S. Ho, J.K. Chua, *Nevus of Ota: a new classification based on the response to laser treatment*, Lasers Surg. Med. **28** (2001) 267-272.
- [4] A. Hidano, H. Kajima, S. Ikeda, H. Mizutani, H. Miyasato, M. Niimura, *Natural history of nevus of Ota*, Arch. Dermatol **95** (1967) 187-195.
- [5] A.W. Kopf, A.I. Weidman, *Nevus of Ota*, Arch. Dermatol, **85** (1962) 195-208.
- [6] Z. Lu, J. Chen, X. Wang, L. Fang, S. Jiao, W. Huang, *Effect of Q-switched alexandrite laser irradiation on dermal melanocytes of nevus of Ota*, Chin. Med. J. (Engl) **113** (2000) 49-52.
- [7] Z. Lu, J. Chen, X. Wang, L. Fang, S. Jiao, W. Huang, *Effect of Q-switched Alexandrite laser irradiation on epidermal melanocytes in treatment of Nevus of Ota*, Chin. Med. J. (Engl) **16** (2003) 597-601.
- [8] Z. Lu, L. Fang, S. Jiao, W. Huang, J. Chen, X. Wang, *Treatment of 522 patients with Nevus of Ota with Q-switched Alexandrite laser*, Chin. Med. J. (Engl) **116** (2003) 226-230.
- [9] G.A. Moreno-Arias, A. Camps-Fresneda, *Treatment of nevus of Ota with the Q-switched alexandrite laser*, Lasers Surg. Med. **28** (2001) 451-455.
- [10] N.K. Rho, W.S. Kim, D.Y. Lee, J.M. Yang, E.S. Lee, J.H. Lee, *Histopathological parameters determining lesion colours in the naevus of 12 Ota: a morphometric study using computer-assisted image analysis*, Br. J. Dermatol **150** (2004) 1148-1153.
- [11] S. Ueda, M. Isoda, S. Imayama, *Response of naevus of Ota to Q-switched ruby laser treatment according to lesion colour*, Br. J. Dermatol **142** (2000) 77-83.
- [12] H.W. Wang, Y.H. Liu, G.K. Zhang, H.Z. Jin, Y.G. Zuo, G.T. Jiang, J.B. Wang, *Analysis of 602 Chinese cases of nevus of Ota and the treatment results treated by Q-switched alexandrite laser*, Dermatol Surg. **33** (2007) 455-460.